Laryngoscope Investigative Otolaryngology

Distribution of Label-Retaining Cells and their Properties in the Vocal Fold Mucosa

Kiminobu Sato, MD; Takashi Kurita, MD; Shun-ichi Chitose, MD; Kiminori Sato, MD; Hirohito Umeno, MD; Hirohisa Yano, MD

Objective: The latest research suggests cells in the maculae flavae (MFe) are putative stem cells of the vocal fold mucosa and the MFe are a candidate for a stem cell niche. Distribution and properties of label-retaining cells (LRCs) in the vocal fold mucosa were investigated.

Study Design: Histologic analysis of the rat vocal folds.

Methods: Oral administration of bromodeoxyuridine (BrdU) was given to rats and the LRCs in the vocal fold mucosa were observed by immunohistochemistry. Immunoreactivity to antibodies directed to BrdU, Ki67, cytokeratin, vimentin, glial fibrillary acidic protein, desmin, Sox17, CD34, CD45, Type I collagen, and CD44 was studied. Extracellular matrices around LRCs were observed by Alcian blue staining and hyaluronidase digestion study.

Results: LRCs were present in the MFe and were resting cells (G0-phase). They expressed epithelium, muscle, neural, and mesenchymal cell–associated intermediate filament proteins, and an endodermal marker, indicating cells in the MFe are undifferentiated and express proteins of all three germ layers. They expressed hematopoietic markers (CD34, CD45) and Type I collagen, which are the major markers of bone marrow derived circulating fibrocytes. The hyaluronan concentration in the MFe was high and the cells in the MFe expressed the surface hyaluronan receptor CD44, indicating that the MFe were a hyaluronan-rich matrix.

Conclusion: LRCs reside in the MFe and MFe had a hyaluronan-rich matrix. The results of this study are consistent with the hypothesis that the cells in the MFe are putative stem cells and the MFe are a candidate for a stem cell niche.

Key Words: label-retaining cells, hyaluronan-rich matrix, vocal fold, tissue stem cells, stem cell niche.

Level of Evidence: N/A

INTRODUCTION

Adult tissue-specific stem cells (tissue stem cells) have the capacity to self-renew and generate functionally differentiated cells that replenish lost cells throughout an organism's lifetime.[1] In recent years, there have been many reports on tissue stem cells and experimental methods to detect them.

Label-retaining cell assay is one of the methods to detect tissue stem cells and has been used in various organs.[2–4] BrdU (bromodeoxyuridine) is commonly used to label a cell's DNA. BrdU labeling is diluted and lost during cell division, consequently, stem cells retain labeling because of their slow cell cycle. Label-retaining cell assay is experimentally used to determine putative stem cells.

As described in detail previously,[5] human maculae flavae located at both ends of the vocal fold mucosa are inferred to be involved in the metabolism of extracellular matrices, which are essential for the viscoelastic properties of the lamina propria of the human vocal fold, and to be responsible for maintaining the characteristic layered structure of the human vocal fold mucosa. As described in detail previously,[6] human maculae flavae are considered to be an important structure in the growth, development and aging of the human vocal fold mucosa.

The previous research shows,[7–11] there is growing evidence to suggest that the cells in the maculae flavae are putative stem cells or progenitor cells of the vocal fold mucosa, and that the maculae flavae are a candidate for a stem cell niche.

The purpose of this study is to investigate the distribution and the properties of label-retaining cells, and microenvironment around the label-retaining cells in the vocal fold mucosa.

MATERIALS AND METHODS

Experimental Animals

All animal experiments were performed with the approval of the Kurume University Animal Care and Treatment Committee (Permit Number. 2017-200). Twelve male 3-week-old Sprague-Dawley rats (Japan SLC, Shizuoka, Japan) were used for this experiment. They were caged individually with free

From the Department of Otolaryngology–Head and Neck Surgery (K.S., T.K., S.C., Kiminori Sato, H.U.), and the Department of Pathology (K.S., H.Y.), Kurume University School of Medicine, Kurume, Japan.

Editor's Note: This Manuscript was accepted for publication 22 September 2018.

The authors declare there is no conflicts of interest in this study.

Send correspondence to Kiminobu Sato, MD, Department of Otolaryngology–Head and Neck Surgery, Kurume University School of Medicine, 67 Asahi-machi, Kurume 830-0011, Japan. Email: satou_kiminobu@med.kurume-u.ac.jp

DOI: 10.1002/lio2.219

access to standard laboratory chow and tap water. Individual cage sizes were 272 millimeters (width) x 434 millimeters (depth) x 203 millimeters (height). The rats health and behaviors were monitored every day.

Label-Retaining Cell Assay

All rats were orally administered 1.0mg/mL bromodeoxyuridine (BrdU) (Sigma-Aldrich, St Louis, MO) dissolved in drinking water for 7 consecutive days. The rat larynges were observed at three separated intervals. Four rats were sacrificed each time at 1, 14, and 56 days after the 7 consecutive days of BrdU administrations and their larynges were harvested.

When rats were sacrificed, they were euthanized by isoflurane and carbonic acid gas. Larynges were fixed in 10% neutral formalin for 6 hours and preserved in 70% ethanol at room temperature. Immunohistochemical staining was carried out to detect label-retaining cells.

BrdU-positive cells in the maculae flavae, the staratified squamous epithelium and the lamina propria of the vocal fold mucosa were counted in 16 fields of vision each (50 μm x 50 μm) on a light microscope at 1, 14, and 56 days. The average percentages of BrdU-positive cells were compared statistically.

Immunohistochemistry

BrdU, Ki-67, cytokeratin, vimentin, glial fibrillary acidic protein (GFAP), desmin, Sox17, CD44, CD34, CD45, Type I collagen were histologically detected in the formalin-fixed and paraffin-embedded tissue by immunohistochemistry, for which a universal immune-enzyme polymer method staining kit (Histofine Simple Stain MAX-PO, Nichirei, Tokyo, Japan) was used. After being dehydrated in a graded concentration of ethanol and embedded in paraffin, all specimens were sectioned to a thickness of 3 μm and mounted on glass slides. After deparaffinization and hydration, slides with specimens were incubated at 99°C in a target retrieval solution (DAKO, Glostrup, Denmark) for 40 minutes. Then, endogenous peroxidase was blocked with 3% hydrogen peroxidase for 10 minutes and nonspecific binding with serum free proteins (DAKO, Glostrup, Denmark) was performed. The specimens were then incubated with monoclonal mouse primary antibody at 4°C overnight. Between all processes, slides with specimens were rinsed with 0.1-mol/L phosphate-buffered saline solution (PBS) at pH 7.4.

A 1:20 diluted monoclonal antibody against BrdU (DAKO, Glostrup, Denmark, mouse monoclonal), a 1:100 against Ki-67 (Abcam, Cambridge, UK, ab16667, rabbit monoclonal), a 1:100 against cytokeratin (Novus biologicals, Abingdon, UK, NBP2-29429, mouse monoclonal), a 1:100 against vimentin (Abcam, Cambridge, UK, ab8978, mouse monoclonal), a 1:100 against GFAP (Abcam, Cambridge, UK, ab10062, mouse monoclonal), a 1:100 against desmin (Abcam, Cambridge, UK, ab6322, mouse monoclonal), a 1:100 against Sox17 (Abcam, Cambridge, UK, ab84990, mouse monoclonal), a 1:250 against CD44 (Abcam, Cambridge, UK, ab157107, rabbit polyclonal), a 1:200 against CD34 (Abcam, Cambridge, UK, ab81289, rabbit monoclonal), a 1:100 against CD45 (Abcam, Cambridge, UK, ab10558, rabbit polyclonal), and a 1:500 against Type I collagen (Abcam plc. Cambridge, UK, ab34710, rabbit polyclonal) were used.

After labeling with the universal immuno-enzyme polymer method staining kit, a color reaction was developed with 3,3'-diaminobenzidine tetrahydrochloride for 5 to 10 minutes at room temperature. Immunoreactivity was examined by light microscopy.

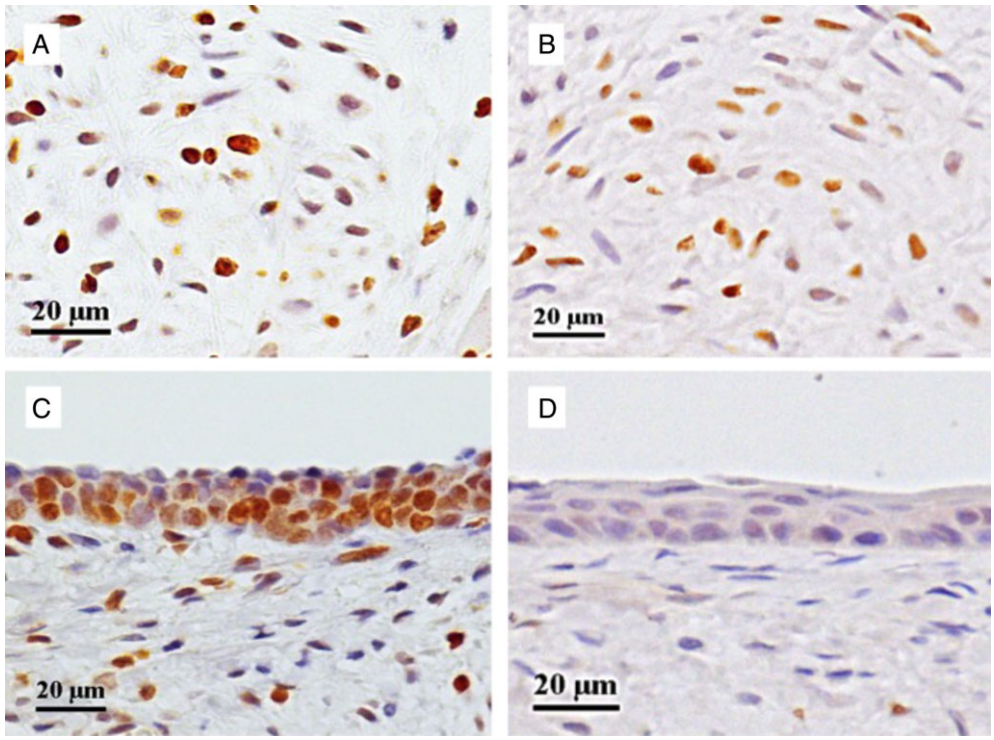

Fig. 1. BrdU-positive cells in the rat vocal fold mucosa. A: Macula flava at day 1 after BrdU administration. B: Macula flava at day 56 after BrdU administration. C: Epithelium and lamina propria of the vocal fold mucosa at day 1 after BrdU administration. D: Epithelium and lamina propria of the vocal fold mucosa at day 56 after BrdU administration. Cells in the maculae flavae retained BrdU for an long period, indicating that they were label-retaining cells.

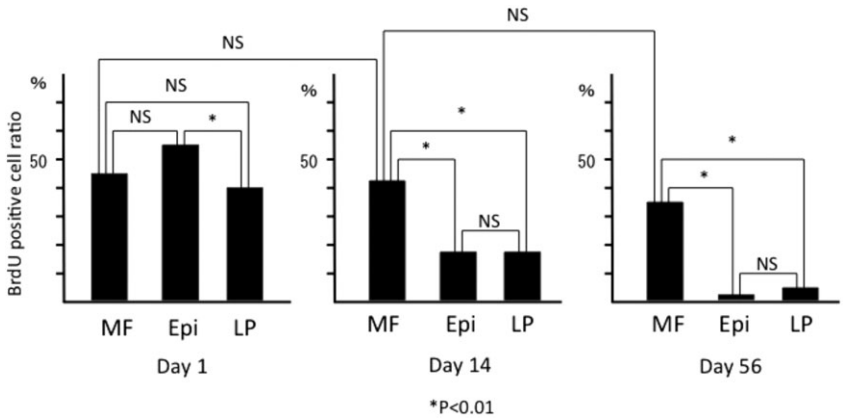

Fig. 2. Mean percentage of BrdU-positive cells in each region of the vocal fold at three separated intervals (day 1, 14, 56). Epi = epithelium; LP = lamina propria of the vocal fold mucosa; MF = maculae flavae. The percentage of BrdU-positive cells in the epithelium and lamina propria of the rat vocal fold mucosa decreased significantly by day 56. On the other hand, BrdU-positive cells in the rat maculae flavae was maintained throgh day 56.

Alcian Blue Staining and Hyaluronidase Digestion Study

Alcian blue staining (pH 2.5) and hyarulonidase digestion study were performed to detect hyaluronic acid. For the hyaluronidase digestion study, 12.5-mg bovine testes hyaluronidase (Sigma, St Louis, MO) was diluted in 100 mL of PBS. The sections were incubated in the diluted hyaluronidase solution for 4 hours at 37°C. The thin sections were subsequently stained with Alcian blue (pH 2.5).

RESULTS

Distribution of Label-Retaining Cells in the Vocal Fold Mucosa

At day 1 after BrdU administration for 7 consecutive days, BrdU-positive cells were identified in basal to superficial layer of the stratified squamous epithelium (54.1 ± 10.3%, mean ± SD%), the lamina propria (41.7 ± 11.6%) and the anterior and posterior maculae flavae (44.8 ± 14.2%) of the vocal fold (Figs. 1 and 2).

At day 14 after BrdU administration, BrdU-positive cells in the stratified squamous epithelium (18.8 ± 3.8%), especially in the superficial layer, and the lamina propria (18.8 ± 11.6%) had decreased compared day 1 ($P < .01$) (Fig. 2). Some BrdU-positive cells remained in the basal layer of the stratified squamous epithelium as well. However, BrdU-positive cells remained in the anterior and posterior maculae flavae (41.4 ± 5.5%) ($P < .01$) (Fig. 2).

At day 56 after administration, the number of BrdU-positive cells was very small in the basal layer of the stratified squamous epithelium (2.4 ± 3.8%) and the lamina propria (6.5 ± 6.5%). However, the number of BrdU-positive cells remaining in the anterior and posterior maculae flavae was high (33.3 ± 12.7%) (Fig. 1). The high BrdU-positive cell ratio in the maculae flavae was maintained though day 56 ($P < .01$)(Fig. 2).

According to these results, label-retaining cells resided in the maculae flavae of the vocal fold.

Cell Cycle of the Cells in the Maculae Flavae

Few Ki-67 positive cells were identified in the maculae flavae (Fig. 3) indicating that the cells in the maculae flavae are in the resting phase (G0 phase).

Intermediate Filaments of the Cells in the Maculae Flavae

Cytokeratin, vimentin, GFAP, and desmin were present in the cells in the macula flavae (Fig. 4), indicating

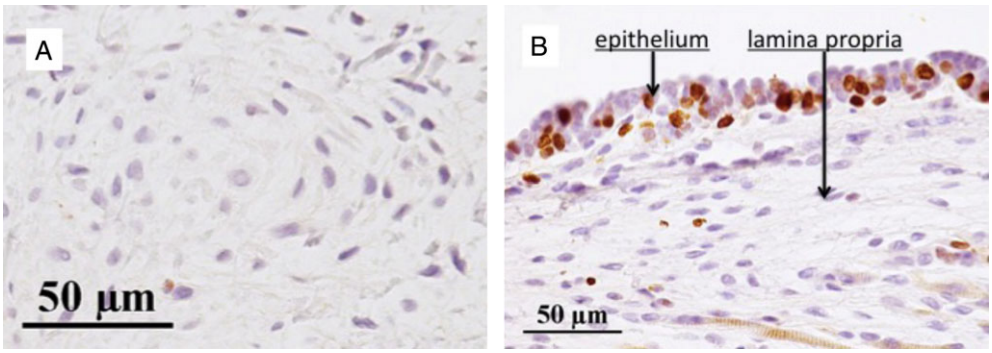

Fig. 3. Ki67 positive cells in the rat vocal fold mucosa. A: Macula flava, B: epithelium and lamina propria of the vocal fold mucosa. Ki-67–positive cells were identified in the basal layer of the stratified squamous epithelium and in the lamina propria of the vocal fold mucosa. Few Ki-67–positive cells were identified in the maculae flavae.

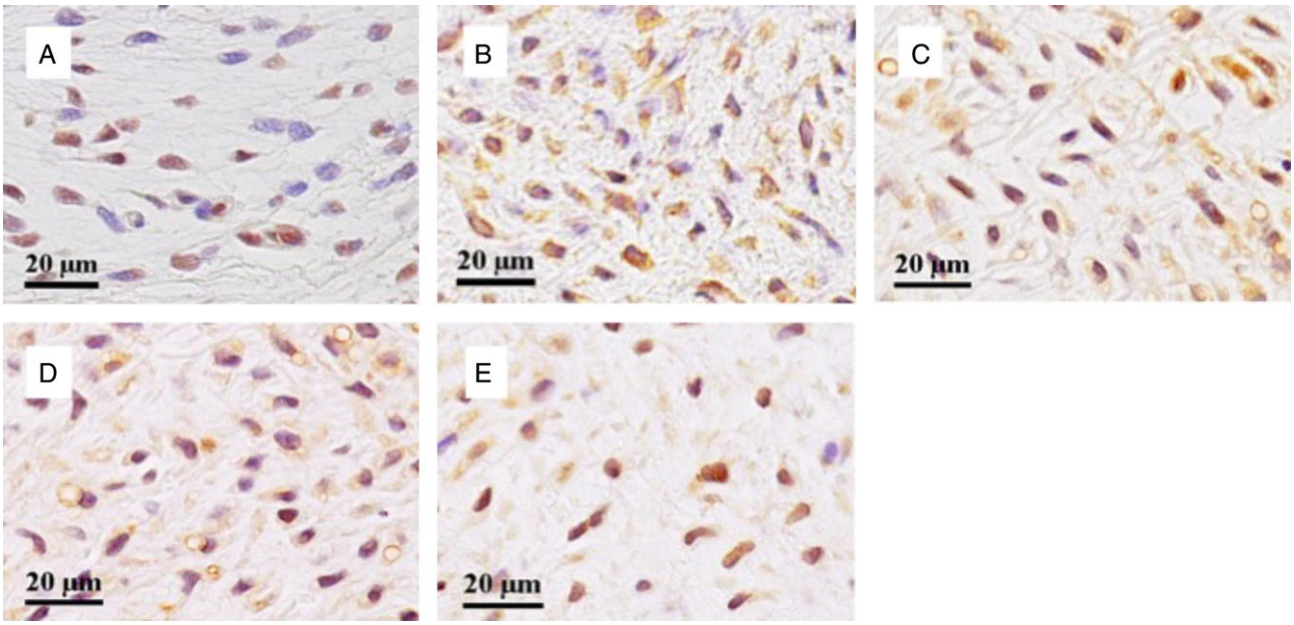

Fig. 4. Immunohistochemical staining of the cells in the maculae flavae of the rat vocal fold. Cytokeratin (A), desmin (B), glial fibrillary acidic protein (C), vimentin (D), and Sox17 (E) immunoreactivity were present. The cells in the maculae flavae express proteins of all three germ layers.

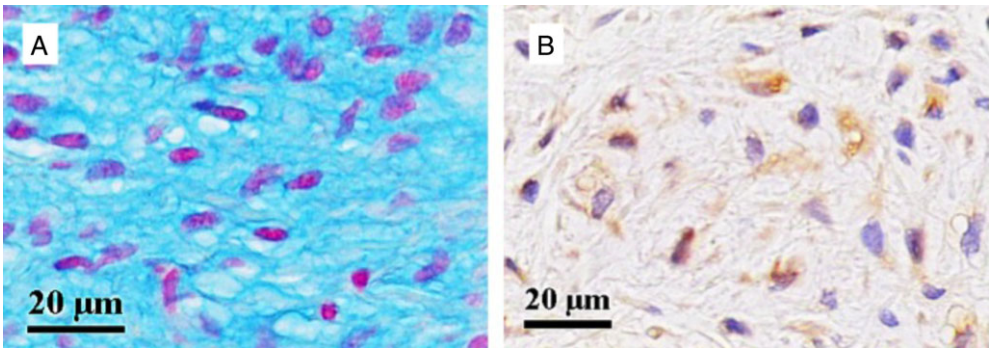

Fig. 5. Macula flava of the rat vocal fold (A: Alcian blue staining, pH 2.5) (B: immunohistochemical staining of CD44). A large amount of the glycosaminoglycan hyaluronan (light blue stained material) is situated around the cells in the macula flava and the cells expressed CD44, a cell surface hyaluronan receptors, indicating the macula flava has a hyaluronan-rich matrix.

that the cells expressed epithelium, muscle, neural, and mesenchymal cell–associated intermediate filaments and expressed proteins of the ectodermal and mesodermal germ layers. In addition, cells in the macula flavae expressed Sox17, an endodermal marker (Fig. 4). These results suggest the cells in the maculae flavae are undifferentiated and express proteins of all three germ layers.

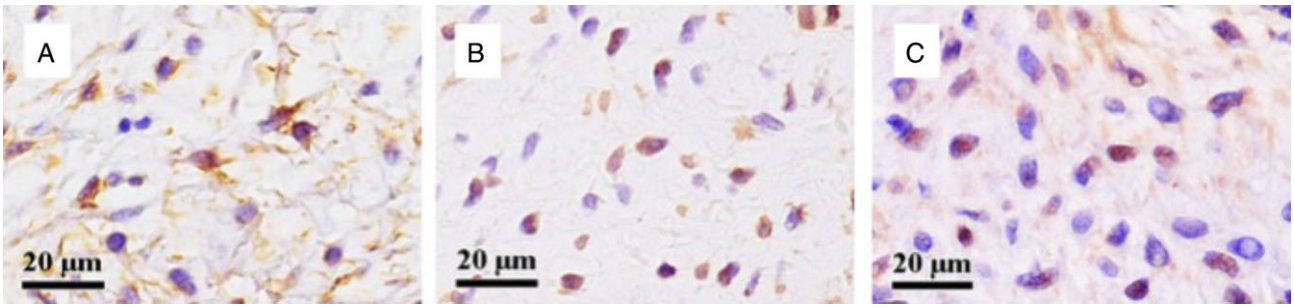

Fig. 6. Immunohistochemical staining of the cells in the macula flava of the rat vocal fold for major markers of bone marrow-derived circulating fibrocytes. CD34 (A), CD45 (B), and Type I collagen (C) were expressed in the cells in the maculae flavae.

Microenvironment Around the Cells in the Maculae Flavae

The anterior and posterior maculae flavae were strongly stained light blue with Alcian blue at pH 2.5 (Fig. 5A). The materials in the maculae flavae that were strongly stained with Alcian blue at pH 2.5 were digested by hyaluronidase. A great deal of hyaluronan was situated around the cells in the maculae flavae. CD44 cell surface hyaluronan receptors were expressed in the cells in the maculae flavae (Fig. 5B), indicating that the maculae flavae were a hyaluronan-rich matrix.

Origin of the Cells in the Maculae Flavae

The cells in the maculae flavae expressed CD34 (hematopoietic progenitor cell marker), CD45 (leukocyte common antigen) and type I collagen (Fig. 6), which are the major makers of bone marrow derived circulating fibrocytes.

DISCUSSION

As described in detail previously,[1] adult tissue-specific stem cells (tissue stem cells) have the capacity to self-renew and generate functionally differentiated cells that replenish lost cells throughout an organism's lifetime. Tissue-specific stem cells reside in a niche, whereby a complex microenvironment maintains their multipotency.

Label-retaining cell assay has been used in many investigations to detect tissue stem cells and their distribution.[2–4]

Label-Retaining Cell Assay

Adult tissue stem cells consistently retain labeled DNA since stem cells divide more infrequently than other cells. BrdU is an analogue of thymidine which incorporates into the cell's DNA during in the S phase of mitosis.

In the present study, just after BrdU administration, BrdU-positive cells were identified in the basal to superficial layer of the stratified squamous epithelium, the lamina propria, and the maculae flavae of the vocal fold mucosa. However, the high BrdU-positive cell ratio in the maculae flavae was maintained through day 56. And therefore, label-retaining cells resided in the anterior and posterior maculae flavae.

Bonhoeffer et al. reported BrdU labeling could be observed for up to five or six cell divisions in human lymphocytes.[12] In addition, Adams et al. reported the doubling time of fibroblasts in the human vocal fold in the primary culture of passage two is 30 hours.[13] And Savelli et al. reported cells in the basal layer epithelium divide every 30 hours under physiologic conditions.[14] If cells in the vocal fold mucosa retain BrdU labeling for up to five or six cell division as lymphocytes do, BrdU labeling could be observed for up to 7 or 8 days in a normal cell cycle.

In the present study, the cells in the maculae flavae retained BrdU labeling at day 56 after BrdU administration, indicating the division cycles of the cells in the maculae flavae are slow and different from other cells in the vocal fold mucosa. Consequently, the cells containing in the anterior and posterior maculae flavae are label-retaining cells.

Cell Cycle of Label-Retaining Cells in the Vocal Fold Mucosa

Tissue stem cells are usually in the resting phase (G0 phase) of the cell cycle in their stem cell niche. Ki-67 is a nuclear protein expressed during all active phases of the cell cycle (G1, S, G2, and M phases).

In the present study, Ki-67-positive cells were detected in the basal layer of the stratified squamous epithelium and lamina propria. However, there were few Ki-67-positive cells in the maculae flavae. This result suggests the cells in the maculae flavae are in the resting phase (G0 phase) in the cell cycle.

The label-retaining cells resided in the maculae flavae and they were in the resting phase (G0 phase) of the cell cycle. Consequently, these results are consistent with the hypothesis that the cells in the maculae flavae are putative stem cells of the vocal fold mucosa.

Cell Differentiation of the Cells in the Maculae Flavae of the Vocal Fold Mucosa

As described in detail previously, intermediate filaments are structural proteins of the cytoplasm and specific to cell type and differentiation.[15] Because of the tissue specificity of intermediate filaments, cells from different tissues can be distinguished on the basis of the intermediate filament protein present.[15]

As described in detail previously, cytokeratin is a structural protein expressed in the epithelial cells, vimentin is a major subunit protein of the intermediate filaments expressed in various kinds of mesenchymal cells, GFAP is a member of the structural protein family specifically expressed in glial cells, desmin is a structural protein of the intermediate filament specifically expressed in muscle cells.[15]

In the present study, immunoreactivities with cytokeratin, vimentin, GFAP, and desmin were present in the cells in the maculae flavae of the vocal fold mucosa. As a result, the cells in the maculae flavae expressed epithelium-associated, mesenchymal cell-associated, neural cell-associated, and muscle-associated proteins, indicating these cells have the ability to differentiate to ectoderm cells and mesoderm cells. In addition, Sox17, an endodermal marker, was expressed in the cells in the maculae flavae. Consequently, the cells in the maculae flavae of the vocal fold mucosa expressed proteins of all three germ layers. The expression of proteins of all three germ layers suggests that the cells in the maculae flavae of the vocal fold mucosa are undifferentiated cells and have the ability of multipotency.

Vocal Fold Stellate Cells in the Maculae Flavae of the Human Vocal Fold Mucosa

Vocal fold stellate cells contained in the human adult maculae flavae were discovered in 2001.[16] As described in

detail previously, they are stellate in shape and possess vitamin A storing lipid droplets, and are considered to be a new category of cells in the human vocal fold.[5,6,16,17] The question arises whether the vocal fold stellate cells are tissue stem cells or progenitor cells (transit-amplifying cells).[10] However, at the present state of our investigation, it is difficult to clarify the stem cell system and hierarchy of stem cells in the human maculae flavae and determine whether the vocal fold stellate cells are putative stem cells or progenitor cells.

Likewise, Tateya et al. reported the cells in the rat maculae flavae also have vitamin A storing lipid droplets.[18] However, at the present state of our investigation, it is also difficult to clarify the stem cell system and hierarchy of stem cells in the rat maculae flavae.

Stem Cell Niche in the Vocal Fold Mucosa

A stem cell niche is a specialized local microenvironment where stem cells reside and which directly promote maintenance of stem cells.[19]

Extracellular matrices are dynamic and complex environments specific to each tissue which also regulate cell behavior.[20] Hyaluronan is one of the extracellular matrix components and serves an important role for numerous stem cell populations.[21,22]

Interactions between extracellular matrices and stem cells can be mediated by cell receptors. CD44 is a cell surface hyaluronan receptor, which has been found to play an important role for hematopoietic stem cell populations.[23]

The latest researches show, a hyaluronan-rich matrix, composed of the glycosaminoglycan hyaluronan and a cell surface receptor (CD44), is able to directly affect the cellular functions of stem cells in a stem cell niche.[21,22]

In the present study, label-retaining cells were surrounded by a high concentration of hyaluronan and CD44 cell surface hyaluronan receptors were present in the cells in the maculae flavae. This result suggests that the microenvironment in the maculae flavae containing label-retaining cells is a hyaluronan-rich matrix and the macula flava is a candidate for a stem cell niche, that is, a microenvironment nurturing a pool of label-retaining cells.

Cell Origin in the Maculae Flavae

Circulating fibrocytes were first described by Bucala et al.[24] As described in detail previously, these cells have been suggested to originate from bone marrow cells, circulate into the blood streams and, after homing to the tissue, differentiate into fibroblasts.[25] The latest research shows, CD34 (hematopoietic stem cell marker), CD45 (leukocyte common antigen) and Type I collagen are major makers for circulating fibrocytes.[25]

In the present study, the cells in the maculae flavae expressed hematopoietic markers (CD34, CD45) and Type I collagen, which are the major makers for bone marrow derived circulating fibrocytes. This result suggests the cells in the maculae flavae arise not from resident interstitial cells but from the differentiation of bone marrow cells.

Putative Stem Cells in the Vocal Fold Mucosa

In recent years, adult tissue stem cells which participate in tissue regeneration and repair, have been detected in various organs.

Yamashita et al. reported side population cells, which are considered to contain high numbers of stem cells or progenitor cells, were identified in the anterior and posterior maculae flavae in the human vocal fold mucosa.[26] Gugatschka et al. reported side population cells in the anterior and posterior maculae flavae participate in the early stages of wound healing of the rat vocal fold.[27]

Kawai et al. reported on the distribution of slow-cycling cells using label-retaining cell assay in the injured rat vocal fold.[28] According to this report, slow-cycling cells, defined as double-labeling cells (immunohistochemically stained with BrdU and Ki-67) were identified in the basal layer of the stratified squamous epithelium of the injured rat vocal fold.[28] Tateya et al. reported that there were few BrdU-positive cells in the maculae flavae of the injured rat vocal fold.[29] Distribution of BrdU-positive cells in the injured vocal fold model is different from the normal one as shown in this study. Consequently, the cells in the maculae flavae may migrate during the wound healing process and may lose BrdU labeling in the injured vocal fold.

Leydon et al. reported that label-retaining cells (BrdU-positive cells) were present in the murine vocal fold epithetium and the percentage of BrdU-positive cells in the murine vocal fold epithelium decreased significantly from 9.4% at 14 days to 3.1% at 56 days.[30] In the present study, the percentage of BrdU-positive cells in the rat vocal fold epithelium also decreased significantly from 18.8% at 14 days to 2.4% at 56 days. On the other hand, the percentage of BrdU-positive cells in the rat maculae flavae was high through day 56 (from 44.8% at 1 day to 41.4% at 14 days and to 33.3% at 56 days). Consequently, label-retaining cells resided in the maculae flavae of the vocal fold mucosa.

CONCLUSION

Label-retaining cells resided in the maculae flavae of the vocal fold mucosa and maculae flavae had a hyaluronan-rich matrix.

The results of this study are consistent with the hypothesis that the maculae flavae are a candidate for a stem cell niche and the cells in the maculae flavae are putative stem cells of the vocal fold mucosa.

BIBLIOGRAPHY

1. Li L, Xie T. Stem cell niche: structure and function. *Annu Rev Cell Dev Biol* 2005;21:605–631.
2. Morris RJ, Potten CS. Slow cycling (label-retaining) epidermal cells behave like clonogenic stem cells in vitro. *Cell Prolif* 1994;27:279–289.
3. Oliver JA, Maarouf O, Cheema FH, Martens TP, Al-Awqati Q. The renal papilla is a niche for adult kidney stem cells. *J Clin Invest* 2004;114: 795–804.

4. Kuwahara R, Kofman AV, Landis CS, Swenson ES, Barendswaard E, Theise ND. The hepatic stem cell niche: identification by label-retaining cell assay. *Hepatology* 2008;47:1994–2002.
5. Sato K, Umeno H, Nakashima T. Functional histology of the macula flava in the human vocal fold. Part 1: Its role in the adult vocal fold. *Folia Phoniatr Logop* 2010;62:178–184.
6. Sato K, Umeno H, Nakashima T. Functional histology of the macula flava in the human vocal fold. Part 2: Its role in the growth and development of the vocal fold. *Folia Phoniatr Logop* 2010;62:263–270.
7. Sato K, Umeno H, Nakashima T. Vocal fold stem cells and their niche in the human vocal fold. *Ann Otol Rhinol Laryngol* 2012;121:798–803.
8. Kurita T, Sato K, Chitose S, Fukahori M, Sueyoshi S, Umeno H. Origin of vocal fold stellate cells in the human macula flava. *Ann Otol Rhinol Laryngol* 2015;124:698–705.
9. Sato K, Chitose S, Kurita T, Umeno H. cell origin in the macula flava of the human newborn vocal fold. *J Laryngol Otol* 2016;130:650–655.
10. Sato K, Chitose S, Kurita T, Umeno H. Microenvironment of macula flava in the human vocal fold as a stem cell niche. *J Laryngol Otol* 2016;130: 656–661.
11. Sato K, Umeno H, Nakashima T. Vocal fold stellate cells in the human macula flava and the diffuse stellate cell system. *Ann Otol Rhinol Laryngol* 2012;121:51–56.
12. Bonhoeffer S, Mohri H, Ho D, Perelson AS. Quantification of cell turnover kinetics using 5-bromo-2'-deoxyuridine. *J Immunol* 2004;164: 5049–5054.
13. Adams GM, Xu CC, Chan RW. Senescence of human vocal fold fibroblasts in primary culture. *J Biomed Sci Eng* 2010;3:148–159.
14. Savelli V, Rizzoli R, Rizzi E, et al. Cell kinetics of vocal fold epithelium in rats. *Boll Soc Ital Bio Sper* 1991;67:1081–1088.
15. Hardin J. Intermediate filament. In: Becker W, Kleinsmith L, Hardin J, (eds). *The World of the Cell*. 6th edn. San Francisco: Pearson Education; 2006:446–450.
16. Sato K, Hirano M, Nakashima T. Stellate cells in the human vocal fold. *Ann Otol Rhinol Laryngol* 2001;110:319–325.
17. Sato K, Hirano M, Nakashima T. Vitamin A-storing stellate cells in the human vocal fold. *Acta Otolaryngol* 2003;123:106–110.
18. Tateya T, Tateya I, Munoz-del-Rio A, Bless DM. Postnatal development of rat vocal folds. *Ann Otol Rhinol Laryngol* 2006;115:215–224.
19. Morrison SJ, Spradling AC. Stem cell and niches: mechanisms that promote stem cell maintenance throughout life. *Cell* 2008;132:598–611.
20. Gattazzo F, Urciuolo A, Bonaldo P. Extracellular matrix: a dynamic microenvironment for stem cell. *Biochim Biophys Acta* 2014;1840:2506–2519.
21. Haylock DN, Nilsson SK. The role of hyaluronic acid in hemopoietic stem cell biology. *Regen Med* 2006;1:437–445.
22. Preston M, Sherman LS. Neural stem cell niches: roles for the hyaluronan-based extracelluar matrix. *Front Biosci (Schol Ed)* 2011;3: 1165–1179.
23. Avigdor A, Goichberg P, Shivtiel S, et al. CD44 and hyaluronic acid cooperate with SDF-1 in the trafficking of human CD34 + stem/progenitor cells to bone marrow. *Blood* 2004;103:2981–2989.
24. Bucala R, Spiegel LA, Chesney J, Hogan M, Cerami A. Circulating fibrocytes define a new leukocyte subpopulation that mediates tissue repair. *Mol Med* 1994;1:71–81.
25. Abedi M. Hematopoietic Origin of Fibrocytes. In: Bucala R, (ed). *Firocytes in Health and Disease*. Singapore: World Scientific Publishing; 2012:1–15.
26. Yamashita M, Hirano S, Kanemaru S, Tsuji S, Suehiro A, Ito J. Side population cells in the human vocal fold. *Ann Otol Rhinol Laryngol* 2007;116: 847–852.
27. Gugatschka M, Kojima T, Ohno S, Kanemaru S, Hirano S. Recruitment patterns of side population cells during wound healing in rat vocal fold. *Laryngoscope* 2011;121:1662–1667.
28. Kawai Y, Kishimoto Y, Suzuki R, et al. Distribution and characteristics of slow-cycling cells in rat vocal folds. *Laryngoscope* 2016;126:E164–E170.
29. Tateya I, Tateya T, Lim X, Sohn JH, Bless DM. Cell production in injured vocal folds: a rat study. *Ann Otol Rhinol Laryngol* 2006;115:135–143.
30. Leydon C, Bartlett RS, Roenneburg DA, Thibeault SL. Localization of label-retaining cells in murine vocal fold epithelium. *J Speech Lang Hear Res* 2011;54:1060–1066.