

# Functional and Structural Outcomes After Retears of Arthroscopically Repaired Large and Massive Rotator Cuff Tears

Suguru Tanaka,\* MD, Masafumi Gotoh,<sup>†‡</sup> MD, PhD, Koji Tanaka,\* MD, PhD, Yasuhiro Mitsui,\* MD, PhD, Hidehiro Nakamura,\* MD, PhD, Hiroki Ozono,\* MD, PhD, Takahiro Okawa,<sup>†</sup> MD, PhD, and Naoto Shiba,\* MD, PhD

*Investigation performed at Kurume University, Kurume, Japan*

**Background:** Most studies have shown acceptable clinical results in patients with large or massive tears treated by arthroscopic rotator cuff repair (ARCR); however, the effects of retears after surgery in these patients remain unknown.

**Purpose:** To evaluate functional and structural outcomes after retears of large and massive rotator cuff tears treated by ARCR.

**Study Design:** Case series; Level of evidence, 4.

**Methods:** A total of 196 consecutive patients with large to massive rotator cuff tears underwent physical examination and magnetic resonance imaging before and after ARCR at 6, 12, and 24 months. Of these, 9 patients were lost at 6 months after surgery. Therefore, 187 patients were followed up for 24 months after surgery; 148 patients showed no postsurgical ruptures. Consequently, the remaining 39 patients with postsurgical ruptures were included in this study (mean age at surgery,  $64.2 \pm 8.7$  years). Functional outcome measures comprised the University of California, Los Angeles (UCLA) and Japanese Orthopaedic Association (JOA) scores. Structural outcome measures consisted of the global fatty degeneration index (GFDI), mediolateral tear size, and residual tendon attachment area as evaluated by our own scoring system.

**Results:** The mean UCLA and JOA scores significantly improved from  $16.3 \pm 3.9$  and  $63.2 \pm 10.7$  preoperatively to  $27.9 \pm 5.5$  ( $P < .0001$ ) and  $84.5 \pm 9.4$  ( $P < .0001$ ) at final follow-up, respectively. The mean mediolateral tear size ( $P = .03$ ,  $.02$ , and  $.02$ , respectively) and residual tendon attachment area ( $P = .04$ ,  $.03$ , and  $.04$ , respectively) significantly improved from preoperatively to 6, 12, and 24 months postoperatively. The correlation analysis between the functional and structural variables confirmed significant associations between the residual tendon attachment area, the JOA and UCLA scores at 24 months postoperatively, and the preoperative GFDI ( $r = -0.81$  to  $0.78$ ).

**Conclusion:** The residual tendon attachment area after a retear was significantly larger at 24 months after surgery than before surgery. In addition, significant associations were confirmed between preoperative fatty degeneration, the residual tendon attachment area, and functional outcomes after a retear. These results may explain why functional outcomes significantly improved even after retears in this series.

**Keywords:** arthroscopic rotator cuff repair; retear; functional outcome; large/massive rotator cuff tears; structural outcome; residual tendon attachment area

Arthroscopic rotator cuff repair (ARCR) has advanced technically, although large to massive rotator cuff tears remain challenging for this surgical procedure. According to Chung et al,<sup>5</sup> the clinical outcomes of ARCR are generally favorable; nevertheless, a substantial postoperative retear remains an immense concern. Carbonel et al<sup>4</sup> reported that larger tears experience an elevated rate of postsurgical relapse, ranging from 10% to 41% in 6 months. At 1- and 2-year follow-up, Galatz et al<sup>7</sup> studied the arthroscopic repair of

larger rotator cuff ruptures; the retear rates after repair ranged from 13% to 94%. Yeo et al<sup>22</sup> indicated that the relapse rate was 7% in tears measuring  $<2 \text{ cm}^2$ , but it reached 44% for those  $>8 \text{ cm}^2$ . Therefore, a postsurgical rupture occurs to a greater extent for massive rotator cuff tears.

ARCR produces good clinical outcomes in patients with large to massive rotator cuff tears, although the outcomes in those with a retear after surgery remain controversial. According to Yoo et al,<sup>23</sup> no significant differences were observed in the postoperative clinical outcomes of patients with or without retears. Chung et al<sup>5</sup> also reported that the anatomic failure rate was 39.8% after the arthroscopic repair of massive rotator cuff tears; however, the functional

status improved, regardless of the presence of postoperative ruptures. In contrast, Mihata et al<sup>10</sup> indicated that postoperative clinical outcomes in patients with retears were significantly worse than those without. Bishop et al<sup>11</sup> demonstrated that functional outcomes, unlike pain, were significantly worse in patients with rotator cuff retears. Therefore, most studies have exclusively analyzed functional but not structural outcomes. The association between postoperative retears and functional outcomes remains unclarified.

In the present study, we focused on both functional and structural outcomes in patients with large to massive rotator cuff tears treated by arthroscopic surgery. We hypothesized that postoperative functional outcomes will be associated with the defect size after a re-tear

## METHODS

This study was approved by an institutional review board, and written informed consent was obtained from all participants.

### Participants

Between April 2005 and March 2015, a total of 196 consecutive patients with large to massive rotator cuff tears underwent ARCR. Of these, 9 patients were lost to follow-up, and 148 patients showed no postsurgical ruptures. The remaining 39 patients experienced a postsurgical rupture and were included in this study. The presence of hypertension, diabetes mellitus, traumatic onset, stiffness, and workers' compensation was collected from standardized patient data records to assess preoperative comorbidities in all patients. Patient characteristics are provided in Table 1.

### Surgical Procedure

ARCR was considered if patients did not respond to nonoperative treatment (anti-inflammatory medication, physical therapy, subacromial or glenohumeral injections of hyaluronic acid or corticosteroids, and activity modification) for  $\geq 3$  months.

ARCR was performed in the beach-chair position under general anesthesia. Initially, the inspection of the glenohumeral joint was performed through a posterior portal, followed by the subacromial bursa. After creating a lateral portal, the detached tendon edge was identified; mobility was evaluated by grasping the edge of the rotator cuff and reducing it to the footprint. By utilizing anterior,

TABLE 1  
Characteristic Variables (n = 39)<sup>a</sup>

Variable	Value
Age, mean $\pm$ SD, y	64.2 $\pm$ 8.7
Sex, male/female, n	24/15
Diabetes	3 (8)
Dominant side affected	25 (64)
Traumatic onset	18 (46)
Symptom duration, wk, mean	39
Hypertension	7 (18)
Stiffness	9 (23)
Workers' compensation	2 (5)

<sup>a</sup>Data are reported as n (%) unless otherwise indicated.

anterolateral, or posterolateral portals, secondary procedures including capsular release and tenotomy/tenodesis of the long head of the biceps tendon were carried out as required. Acromioplasty was performed using the suture bridge technique in all patients. In large to massive tear cases, the suture bridge technique is sometimes unfeasible because of severe retraction and poor tissue quality.

### Postoperative Rehabilitation Protocol

Patients were immobilized utilizing a sling and an abduction pillow; they were instructed to maintain their shoulder at an internal rotation of 30° or 40° and at 20° of abduction after surgery. Subsequently, elbow, wrist, and finger range of motion (ROM) exercises were initiated. At postoperative week 4, passive shoulder ROM exercises were begun, followed by active ROM exercises at week 7, isometric muscle strengthening exercises at week 8, and isotonic muscle strengthening exercises at week 12.

### Structural Assessment

All patients underwent magnetic resonance imaging (MRI) preoperatively and at 6, 12, and 24 months after surgery to assess tendon integrity, the mediolateral tear size, and fatty degeneration (1.5 T [Toshiba] from 2005 to 2013 and 3.0 T [Siemens] from 2013 to 2015). Through T2-weighted imaging, the detection of a fluid-equivalent signal or nonvisualization of the rotator cuff tendon resulted in the diagnosis of a full-thickness tear or postsurgical rupture.<sup>10,17</sup> Fatty degeneration of the rotator cuff muscles was examined by MRI and evaluated for each shoulder in the "Y view" of T2-weighted images according to the modified Goutallier classification.<sup>15</sup> Subsequently, we calculated the global fatty degeneration index (GFDI) as the mean value of the grades for each

<sup>‡</sup>Address correspondence to Masafumi Gotoh, MD, PhD, Kurume University Medical Center, 155-1 Kokubu-machi, Kurume, Fukuoka 839-0863, Japan (email: gomasa@med.kurume-u.ac.jp).

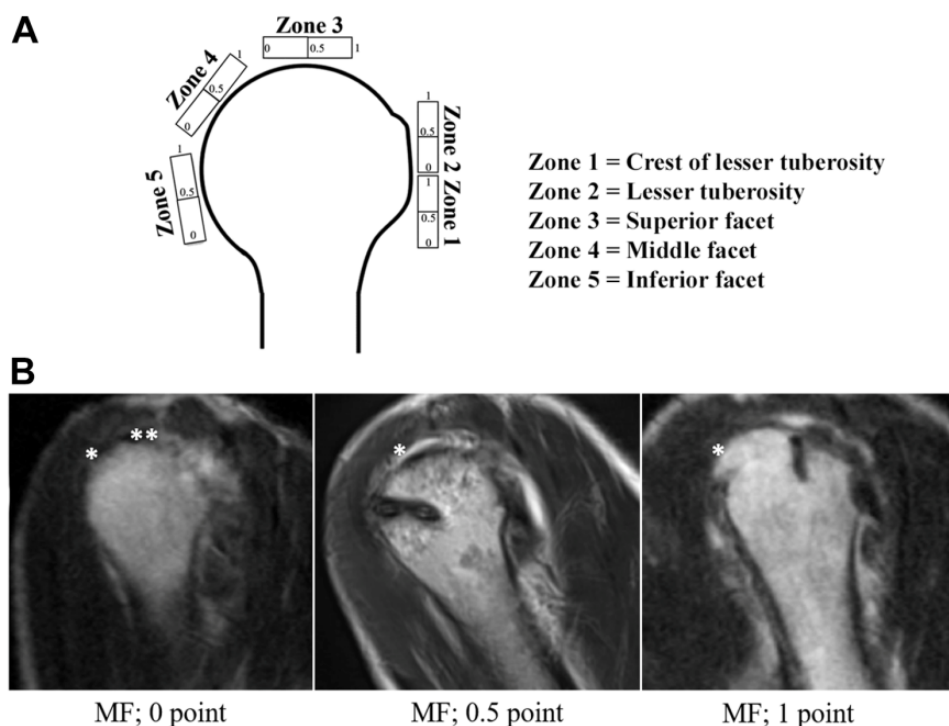
<sup>\*</sup>Department of Orthopedic Surgery, Kurume University School of Medicine, Kurume, Japan.

<sup>†</sup>Department of Orthopedic Surgery, Kurume University Medical Center, Kurume, Japan.

Final revision submitted March 8, 2021; accepted April 14, 2021.

The authors have declared that there are no conflicts of interest in the authorship and publication of this contribution. AOSSM checks author disclosures against the Open Payments Database (OPD). AOSSM has not conducted an independent investigation on the OPD and disclaims any liability or responsibility relating thereto.

Ethical approval for this study was obtained from Kurume University Hospital (No. 17110).



**Figure 1.** Scoring system for the residual tendon attachment area. (A) The rotator cuff footprint was divided into 5 zones, and each zone was scored according to the extent of the residual tendon attachment: 0 points for no tendon attachment, 0.5 points for tendon attachment  $\leq 50\%$  of the zone, and 1.0 point for full tendon attachment or  $>50\%$  of the zone. (B) Representative scoring of zone 4, the middle facet (MF), on T2-weighted magnetic resonance imaging (MRI) of retears in 3 left shoulders. Asterisks indicate no tendon attachment seen at the \*superior facet on all 3 MRI scans or the \*\*middle facet on the left MRI scan.

rotator cuff muscle. The mediolateral tear size was defined as the maximum defect size on sagittal oblique images.<sup>6</sup>

The residual tendon attachment area was evaluated by our own scoring system, created by modifying the Lädermann et al<sup>8</sup> and Nakamura et al<sup>12</sup> classifications. The rotator cuff footprint was divided into 5 components: zone 1, crest of the lesser tuberosity; zone 2, lesser tuberosity; zone 3, superior facet; zone 4, middle facet; and zone 5, inferior facet. Each zone was scored according to the extent of the residual tendon attachment: 0 points for no tendon attachment, 0.5 points for tendon attachment  $\leq 50\%$  of the zone, and 1.0 point for full tendon attachment or  $>50\%$  of the zone (Figure 1A). The combined scores of the 5 zones (maximum, 5 points) were calculated and used as a variable, representing the residual tendon attachment area before and after surgery. Representative data are displayed in Figure 1B.

To assess the reproducibility of the grading system, a random sample of 150 components (zones 1-5) from 30 patients was reviewed twice by 2 observers. Both reviewers were orthopaedic surgeons with experience in shoulder surgery and imaging for at least 5 years.

### Functional Assessment

Physical examinations were performed by an independent therapist blinded to the study. The University of California, Los Angeles (UCLA) and Japanese Orthopaedic Association (JOA) scores were used as functional outcome measures.

ROM in flexion, abduction, external rotation, and internal rotation were assessed by a goniometer (Plastic Goniometer; OG Wellness); internal rotation was measured at the highest vertebral level reached by the thumb at the back. Pain was recorded on a 100-point visual analog scale (VAS; 100 = most severe) during 3 states (at rest, during active motion, and at night). ROM and UCLA and JOA scores were evaluated preoperatively and at 6, 12, and 24 months postoperatively, and VAS scores were evaluated preoperatively and at 24 months postoperatively.

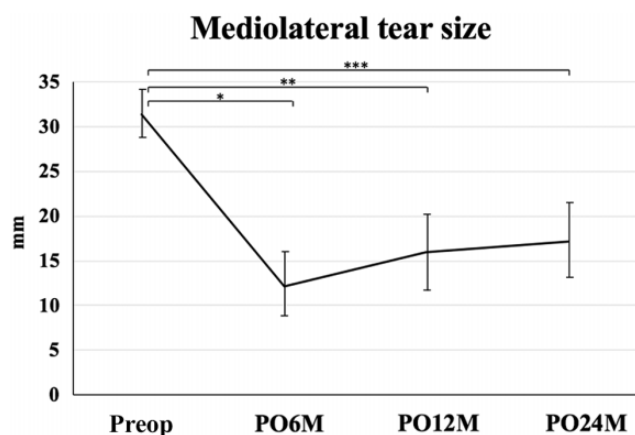
### Statistical Analysis

Data are reported as means and standard deviations. The Wilcoxon test was used to compare the UCLA and JOA scores before and after surgery. The association between 7 variables (preoperative and 24-month postoperative mediolateral tear size and preoperative and 24-month residual tendon attachment area, 24-month postoperative JOA and UCLA scores, and preoperative GFDDI) was evaluated using the Spearman rank correlation coefficient ( $7 \times 7$  comparison). Intraobserver and interobserver agreement for mediolateral tear size were evaluated using the intraclass correlation coefficient, where 0.81 to 1.00 was considered very good agreement, 0.61 to 0.80 good, 0.41 to 0.60 moderate, 0.21 to 0.40 fair, and 0.00 to 0.20 poor. JMP 13 software (SAS Institute) was used for statistical analysis. A  $P$  value  $< .05$  was considered statistically significant.

TABLE 2  
Preoperative Goutallier Classification<sup>a</sup>

Goutallier Stage	Value
Supraspinatus	
Stage 0	0
Stage 1	8
Stage 2	19
Stage 3	12
Stage 4	0
Infraspinatus	
Stage 0	4
Stage 1	20
Stage 2	15
Stage 3	0
Stage 4	0
Subscapularis	
Stage 0	13
Stage 1	14
Stage 2	11
Stage 3	1
Stage 4	0
Teres minor	
Stage 0	21
Stage 1	18
Stage 2	0
Stage 3	0
Stage 4	0
GFDI, mean $\pm$ SD	1.64 $\pm$ 0.88

<sup>a</sup>Data are reported as No. of shoulders unless otherwise indicated. GFDI, global fatty degeneration index.



**Figure 2.** Changes in the mediolateral tear size from preoperatively to postoperatively (PO). Asterisks indicate a significant difference between preoperatively and \*6 months postoperatively ( $P = .03$ ), \*\*12 months postoperatively ( $P = .02$ ), and \*\*\*24 months postoperatively ( $P = .02$ ).

## RESULTS

### Structural Outcomes

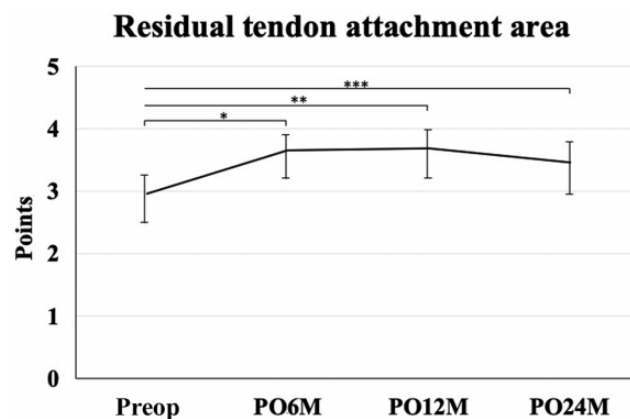
The degree of preoperative fatty degeneration was evaluated by the modified Goutallier classification.<sup>15</sup> Data are summarized in Table 2.

TABLE 3  
Residual Tendon Attachment Area Scores<sup>a</sup>

	Preoperative	6 mo	12 mo	24 mo
Zone 1	1.00	1.00	1.00	1.00
Zone 2	0.93 $\pm$ 0.17	0.98 $\pm$ 0.08	0.99 $\pm$ 0.03	0.84 $\pm$ 0.23
Zone 3	0.00	0.28 $\pm$ 0.25 <sup>b</sup>	0.30 $\pm$ 0.19 <sup>b</sup>	0.28 $\pm$ 0.25 <sup>b</sup>
Zone 4	0.14 $\pm$ 0.23	0.40 $\pm$ 0.31 <sup>b</sup>	0.40 $\pm$ 0.34 <sup>b</sup>	0.35 $\pm$ 0.33 <sup>b</sup>
Zone 5	1.00	1.00	1.00	1.00
Overall	2.97 $\pm$ 0.23	3.66 $\pm$ 0.54 <sup>b</sup>	3.69 $\pm$ 0.61 <sup>b</sup>	3.47 $\pm$ 0.75 <sup>b</sup>

<sup>a</sup>Data are reported as mean  $\pm$  SD.

<sup>b</sup>Significantly different from preoperative score ( $P < .05$ ).



**Figure 3.** Overall changes in the residual tendon attachment area from preoperatively to postoperatively (PO). Asterisks indicate a significant difference between preoperatively and \*6 months postoperatively, \*\*12 months postoperatively, and \*\*\*24 months postoperatively ( $P < .05$  for all).

The mean mediolateral tear size significantly decreased from 32  $\pm$  7.46 mm preoperatively to 13  $\pm$  5.03 mm at 6 months, 16  $\pm$  7.10 mm at 12 months, and 18  $\pm$  7.40 mm at 24 months postoperatively ( $P = .03$ , .02, and .02, respectively) (Figure 2).

For the residual tendon attachment area, the intraobserver and interobserver agreement values of our scoring system were very good (intraclass correlation coefficient = 0.87 and 0.90, respectively). The results indicated that at zones 1 and 5, there was a consistent score of 1 throughout the evaluations. At zone 2, no significant difference in scores was observed from preoperatively to final follow-up. At zones 3 and 4, a significant improvement was seen between the preoperative score versus the 6-, 12-, and 24-month postoperative scores ( $P < .05$  for all). The mean total score also significantly improved from 2.97  $\pm$  0.23 preoperatively to 3.66  $\pm$  0.54 at 6 months, 3.69  $\pm$  0.61 at 12 months, and 3.47  $\pm$  0.75 at final follow-up ( $P < .05$  for all). Details are provided in Table 3 and Figure 3.

### Functional Outcomes

Functional outcomes at all postoperative time points improved significantly from the preoperative assessment,

TABLE 4  
Functional Outcomes<sup>a</sup>

	Preoperative	6 mo	12 mo	24 mo
Range of motion, deg				
Flexion	105.0 ± 39.3	111.0 ± 35.2	118.0 ± 32.7 <sup>b</sup>	125.0 ± 28.1 <sup>b</sup>
Abduction	107.4 ± 48.6	118.6 ± 40.6	124.8 ± 36.9 <sup>b</sup>	134.3 ± 31.8 <sup>b</sup>
External rotation	35.6 ± 18.3	43.5 ± 14.3	50.1 ± 13.3 <sup>b</sup>	54.3 ± 14.8 <sup>b</sup>
Internal rotation	34.1 ± 11.2	37.0 ± 11.1	42.2 ± 10.8 <sup>b</sup>	45.5 ± 10.7 <sup>b</sup>
VAS pain score				
At rest	41.0 ± 31.6	—	—	35.0 ± 37.3 <sup>b</sup>
During active motion	67.8 ± 22.9	—	—	36.0 ± 36.4 <sup>b</sup>
At night	57.8 ± 31.5	—	—	33.1 ± 31.9 <sup>b</sup>
UCLA score	16.3 ± 3.9	21.7 ± 3.6 <sup>b</sup>	24.6 ± 4.7 <sup>c</sup>	27.9 ± 5.5 <sup>c</sup>
JOA score	63.2 ± 10.7	69.5 ± 6.9 <sup>b</sup>	75.1 ± 8.3 <sup>c</sup>	84.5 ± 9.4 <sup>c</sup>

<sup>a</sup>Data are reported as mean ± SD. JOA, Japanese Orthopaedic Association; UCLA, University of California, Los Angeles; VAS, visual analog scale.

<sup>b</sup>Significantly different from preoperative score ( $P < .05$ ).

<sup>c</sup>Significantly different from preoperative score ( $P < .01$ ).

as indicated in Table 4. Flexion ROM improved from 105.0° ± 39.3° preoperatively to 125.0° ± 28.1° at final follow-up ( $P < .05$ ), abduction ROM improved from 107.4° ± 48.6° preoperatively to 134.3° ± 31.8° at final follow-up ( $P < .05$ ), external rotation ROM improved from 35.6° ± 18.3° preoperatively to 54.3° ± 14.8° at final follow-up ( $P < .05$ ), and internal rotation ROM improved from 34.1° ± 11.2° preoperatively to 45.5° ± 10.7° at final follow-up ( $P < .05$ ). All VAS pain scores decreased from preoperatively to postoperatively (at rest: from 41.0 ± 31.6 to 35.0 ± 37.3 [ $P = .04$ ]; during active motion: from 67.8 ± 22.9 to 36.0 ± 36.4 [ $P = .02$ ]; at night: from 57.8 ± 31.5 to 33.1 ± 31.9 [ $P = .02$ ]). The UCLA score improved from 16.3 ± 3.9 preoperatively to 27.9 ± 5.5 at final follow-up ( $P < .0001$ ), and the JOA score improved from 63.2 ± 10.7 preoperatively to 84.5 ± 9.4 at final follow-up ( $P < .0001$ ).

Regarding patients with preoperative pseudopalsy (ie, active flexion <90°;  $n = 17$ ), the mean flexion ROM significantly improved from 68.5° ± 19.6° before surgery to 78.5° ± 13.4° at 6 months, 88.2° ± 14.1° at 12 months, and 101.7° ± 24.6° at final follow-up ( $P < .05$ ). The mean abduction ROM significantly improved from 71.4° ± 38.5° preoperatively to 88.2° ± 34.8° at 6 months, 98.2° ± 30.6° at 12 months, and 112.3° ± 29.6° at final follow-up ( $P < .05$ ). The mean external rotation ROM significantly improved from 32.6° ± 15.1° preoperatively to 40.8° ± 13.7° at 6 months, 50.1° ± 12.6° at 12 months, and 54.4° ± 14.3° at final follow-up ( $P < .05$ ). The mean internal rotation ROM significantly improved from 31.4° ± 11.4° preoperatively to 34.1° ± 11.2° at 6 months, 38.2° ± 10.8° at 12 months, and 41.7° ± 9.8° at final follow-up ( $P < .05$ ).

#### Correlation Between Functional and Structural Variables

Significant positive or negative correlations were observed between the JOA and UCLA scores at 24 months postoperatively, the preoperative GFDI, and both preoperative and 24-month postoperative residual tendon attachment

area ( $r = -0.84$  to 0.78;  $P < .0001$  for all). Details are provided in Table 5.

#### DISCUSSION

Most patients treated with ARCR may have acceptable functional outcomes, regardless of postoperative structural integrity. Previous studies<sup>1,2,7,13</sup> have demonstrated that patients with ruptures after ARCR display significant improvement compared with the preoperative state; however, there is a lack of evidence directly evaluating the association between functional and structural outcomes in patients with a postoperative retear. Therefore, we focused on the functional and structural outcomes in patients with retears after ARCR and successfully demonstrated significant relationships between them.

Previous studies<sup>19-21</sup> using ultrasonography or MRI have demonstrated tear propagation in symptomatic and asymptomatic rotator cuff muscles either treated nonoperatively or operatively observed; however, the association with clinical outcomes was not evaluated. Likewise, few studies have addressed both the functional and structural outcomes in patients with retears after ARCR. The present study demonstrated that UCLA and JOA scores significantly improved at final follow-up from preoperatively. The residual tendon attachment area was detected at 6 months and was significantly larger than the preoperative area; however, this tendon area was maintained at 24 months postoperatively. These structural findings may have contributed to the satisfactory functional outcomes after retears in the present study.

Of particular importance, a significant negative correlation was established after a retear between preoperative fatty degeneration and functional outcomes in terms of the residual tendon attachment area at final follow-up. Fatty degeneration of the rotator cuff muscles contributes to retears after surgery<sup>9</sup> and relatively progresses in large to massive rotator cuff ruptures.<sup>15</sup> In these changes,

TABLE 5  
Correlation ( $r$ ) Between Variables ( $7 \times 7$  Analysis)<sup>a</sup>

	JOA Score at 24 mo	UCLA Score at 24 mo	Preoperative Residual Tendon Attachment Area	Residual Tendon Attachment Area at 24 mo	Preoperative Mediolateral Tear Size	Mediolateral Tear Size at 24 mo	Preoperative GFDI
JOA score at 24 mo	—	0.76 <sup>b</sup>	0.41 <sup>b</sup>	0.67 <sup>b</sup>	0.02	-0.12	-0.61 <sup>b</sup>
UCLA score at 24 mo	0.76 <sup>b</sup>	—	0.34 <sup>b</sup>	0.78 <sup>b</sup>	0.08	0.11	-0.75 <sup>b</sup>
Preoperative residual tendon attachment area	0.41 <sup>b</sup>	0.34 <sup>b</sup>	—	—	0.13	-0.13	-0.34 <sup>b</sup>
Residual tendon attachment area at 24 mo	0.67 <sup>b</sup>	0.78 <sup>b</sup>	—	—	-0.01	-0.20	-0.81 <sup>b</sup>
Preoperative mediolateral tear size	0.02	0.08	0.13	-0.01	—	—	0.13
Mediolateral tear size at 24 mo	0.12	0.11	-0.13	-0.20	—	—	0.28
Preoperative GFDI	-0.61 <sup>b</sup>	-0.75 <sup>b</sup>	-0.34 <sup>b</sup>	-0.81 <sup>b</sup>	0.13	0.28	—

<sup>a</sup>GFDI, global fatty degeneration index; JOA, Japanese Orthopaedic Association; UCLA, University of California, Los Angeles.

<sup>b</sup>Statistically significant correlation ( $P < .05$ ).

Goutallier stage 2 is the cutoff for worsened functional outcomes after surgery<sup>14</sup>; in the present study, the mean GFDI (1.64) was less than stage 2. These results may have equally contributed to the satisfactory functional outcomes observed in the present study.

The importance of a balanced force couple in rotator cuff repair, which involves the anterior subscapularis and posterior infraspinatus, is well known.<sup>3,18</sup> Cavity compression caused by the subscapularis and infraspinatus tendons aids in the centralization of the humeral head. It resists superior translation, despite the pull of the deltoid muscle during abduction. This force balance can offer compression of the humeral head into the glenoid cavity, despite the presence of a significant residual rotator cuff defect, as seen in the present study. The extent of the residual tendon attachment at the anterior and posterior facets was consistently maintained relative to preoperatively.

In contrast, isolated supraspinatus tears are compensated for by the other rotator cuff muscles; thus, they do not contribute to joint instability.<sup>16</sup> Mochizuki et al<sup>11</sup> reported that the footprint of the supraspinatus on the greater tuberosity is much smaller than believed. This area is occupied by a substantial amount of the infraspinatus.<sup>11</sup> The study results suggest that rotator cuff tears previously thought to involve only the supraspinatus tendon may, in fact, have had a substantial infraspinatus component as well. This might have contributed to the satisfactory functional outcomes after retears in the present study.

Some limitations should be considered while interpreting the present findings. First, a limited number of patients were enrolled in this study; therefore, the power analysis was limited. Second, the present study included a retrospective cohort, which may have introduced selection bias and a confounding effect. Third, the follow-up period was restricted to 24 months postoperatively; therefore, tear propagation would have progressed thereafter and may have affected the reliability of the data. A strong point of the study was that the patients were sequentially observed at 6 to 24 months postoperatively. This increased the chances of detecting functional and structural effects of a

retear in patients with large to massive rotator cuff ruptures treated by arthroscopic surgery.

## CONCLUSION

This study examined patients with large to massive rotator cuff ruptures who had retears at 6 months after ARCR and evaluated functional and structural outcomes within 24 months postoperatively. The residual tendon attachment area after a retear at 6 months was significantly larger than preoperatively and was retained at 24 months postoperatively. The present study also confirmed significant associations between preoperative fatty degeneration, the residual tendon attachment area, and functional outcomes after a retear. These results may explain why the functional outcomes significantly improved even after a retear occurred in this series.

## ACKNOWLEDGMENT

The authors thank Dr Tatsuyuki Kakuma for his statistical assistance and Editage ([www.editage.com](http://www.editage.com)) for English language editing.

## REFERENCES

1. Bishop J, Klepps S, Lo IK, Bird J, Gladstone JN, Flatow EL. Cuff integrity after arthroscopic versus open rotator cuff repair: a prospective study. *J Shoulder Elbow Surg*. 2006;15(3):290-299.
2. Boileau P, Brassart N, Watkinson DJ, Carles M, Hatzidakis AM, Krishnan SG. Arthroscopic repair of full-thickness tears of the supraspinatus: does the tendon really heal? *J Bone Joint Surg Am*. 2005;87(6):1229-1240.
3. Burkhart SS, Nottage WM, Ogilvie-Harris DJ, et al. Partial repair of irreparable rotator cuff tears. *Arthroscopy*. 1994;10(4):363-370.
4. Carbonel I, Martínez AA, Aldea E, Ripalda J, Herrera A. Outcome and structural integrity of rotator cuff after arthroscopic treatment of large and massive tears with double row technique: a 2-year follow-up. *Adv Orthop*. 2013;41:1674-1683.
5. Chung SW, Kim JY, Kim MH, Kim SH, Oh JH. Arthroscopic repair of massive rotator cuff tears: outcome and analysis of factors

- associated with healing failure or poor postoperative function. *Am J Sports Med.* 2013;41(7):1674-1683.
6. Davidson JJ, Burkhart SS, Richards DP, Campbell SE. Use of preoperative magnetic resonance imaging to predict rotator cuff tear pattern and method of repair. *Arthroscopy.* 2005;21(12):1428.e1-1428.e10.
  7. Galatz LM, Ball CM, Teefey SA, Middleton WD, Yamaguchi K. The outcome and repair integrity of completely arthroscopically repaired large and massive rotator cuff tears. *J Bone Joint Surg Am.* 2004;86(2):219-224.
  8. Lädermann A, Denard PJ, Collin P. Massive rotator cuff tears: definition and treatment. *Int Orthop.* 2015;39(12):2403-2414.
  9. Lee YS, Jeong JY, Park CD, Kang SG, Yoo JC. Evaluation of the risk factors for a rotator cuff retear after repair surgery. *Am J Sports Med.* 2017;45(8):1755-1761.
  10. Mihata T, Watanabe C, Fukunishi K, et al. Functional and structural outcomes of single-row versus double-row versus combined double-row and suture-bridge repair for rotator cuff tears. *Am J Sports Med.* 2011;39(10):2091-2098.
  11. Mochizuki T, Sugaya H, Uomizu M, et al. Humeral insertion of the supraspinatus and infraspinatus: new anatomical findings regarding the footprint of the rotator cuff. *J Bone Joint Surg Am.* 2008;90(5):962-969.
  12. Nakamura H, Gotoh M, Mitsui Y, et al. Factors affecting clinical outcome in patients with structural failure after arthroscopic rotator cuff repair. *Arthroscopy.* 2016;32(5):732-739.
  13. Nho SJ, Brown BS, Lyman S, Adler RS, Altchek DW, MacGillivray JD. Prospective analysis of arthroscopic rotator cuff repair: prognostic factors affecting clinical and ultrasound outcome. *J Shoulder Elbow Surg.* 2009;18(1):13-20.
  14. Ohzono H, Gotoh M, Nakamura H, et al. Effect of preoperative fatty degeneration of the rotator cuff muscles on the clinical outcome of patients with intact tendons after arthroscopic rotator cuff repair of large/massive cuff tears. *Am J Sports Med.* 2017;45(13):2975-2981.
  15. Park JW, Jo CH, Shin JS. Changes of fatty infiltration according to the immediate postoperative time point in magnetic resonance imaging after arthroscopic rotator cuff repair. *Knee Surg Sports Traumatol Arthrosc.* 2015;26(1):152-160.
  16. Porcellini G, Castagna A, Cesari E, et al. Partial repair of irreparable supraspinatus tendon tears: clinical and radiographic evaluations at long-term follow-up. *J Shoulder Elbow Surg.* 2011;20(7):1170-1177.
  17. Shirachi I, Gotoh M, Mitsui Y, et al. Collagen production at the edge of ruptured rotator cuff tendon is correlated with postoperative cuff integrity. *Arthroscopy.* 2011;27(9):1173-1179.
  18. Thompson WO, Debski RE, Boardman ND III, et al. A biomechanical analysis of rotator cuff deficiency in a cadaveric model. *Am J Sports Med.* 1996;24(3):286-292.
  19. Yamaguchi K, Ditsios K, Middleton WD, Hildebolt CF, Galatz LM, Teefey SA. The demographic and morphological features of rotator cuff disease: a comparison of asymptomatic and symptomatic shoulders. *J Bone Joint Surg Am.* 2006;88(8):1699-1704.
  20. Yamaguchi K, Tetro AM, Blam O, Evanoff BA, Teefey SA, Middleton WD. Natural history of asymptomatic rotator cuff tears: a longitudinal analysis of asymptomatic tears detected sonographically. *J Shoulder Elbow Surg.* 2001;10(3):199-203.
  21. Yamamoto N, Mineta M, Kawakami J, Sano H, Itoi E. Risk factors for tear progression in symptomatic rotator cuff tears: a prospective study of 174 shoulders. *Am J Sports Med.* 2017;45(11):2524-2531.
  22. Yeo DY, Walton JR, Lam P, Murrell GA. The relationship between intraoperative tear dimensions and postoperative pain in 1624 consecutive arthroscopic rotator cuff repairs. *Am J Sports Med.* 2016;45(4):788-793.
  23. Yoo JC, Ahn JH, Koh KH, Lim KS. Rotator cuff integrity after arthroscopic repair for large tears with less-than-optimal footprint coverage. *Arthroscopy.* 2009;25(10):1093-1100.